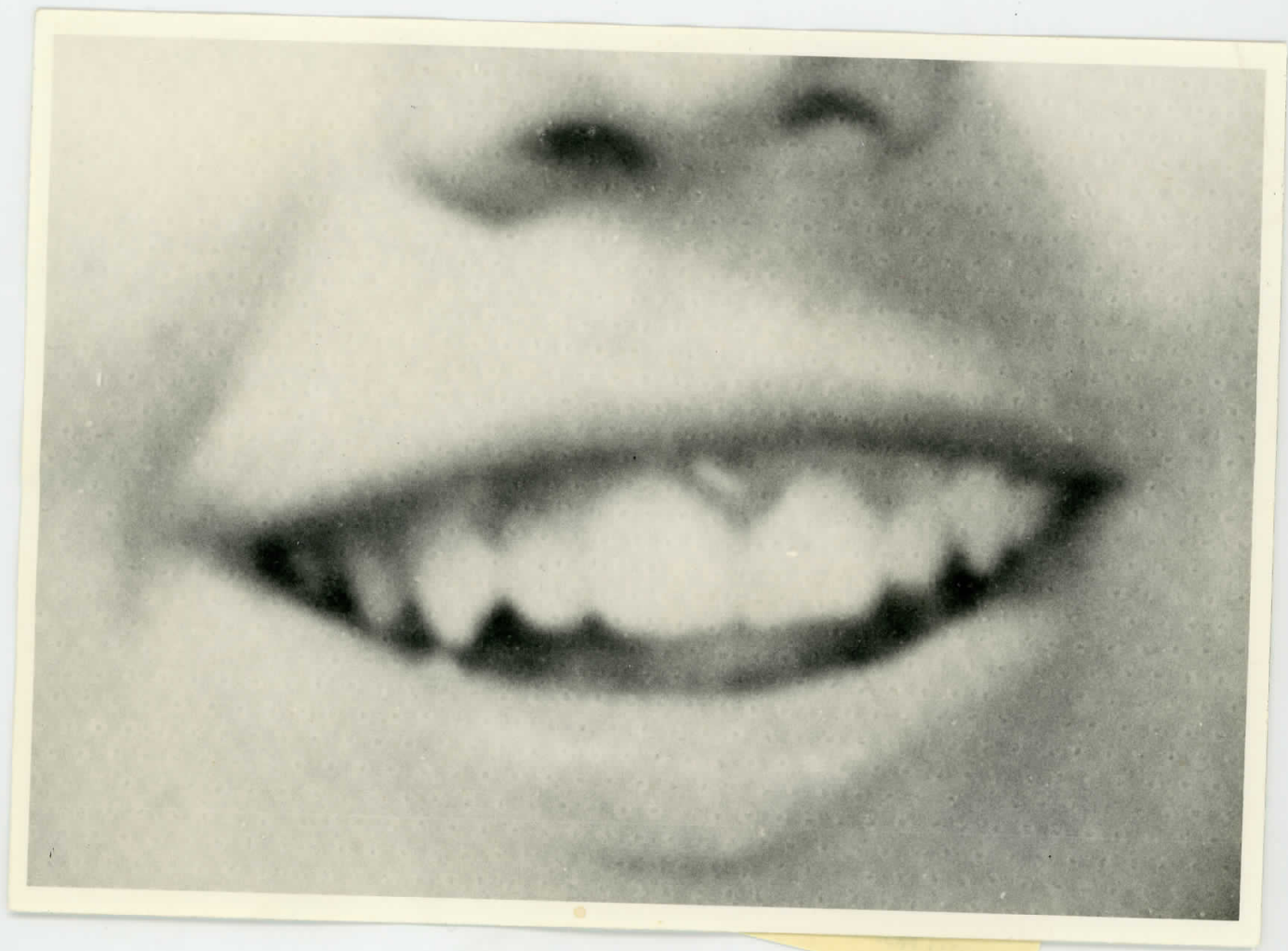



6-13-85

in correct: this is not Branch,
Probably Scott

~~73-3350~~

~~KNOWN photo of RUSTY BRANCH~~

ST. JOSEPH HOSPITAL
DEPT. OF AUDIO-VISUAL
1919 LA BRANCH 77002
HOUSTON, TEXAS
PHOTO NO. 8428 # 26A

8-23-73

Dr Waller; re Mike Scott
ASU rt thigh - thru April '71
base left thumb fracture

not since '70 has he seen him

#15

73-3355
4500-silver bell

No clothes

Dark brown hair. 7 1/2 inches approx.

Asphyxia

Age around 20 yrs.

1 bifid rib

Rt 9th rib fractured posteriorly

36 inches from ankle bone to hip.

Length of body - estimate

71 3/4 - 72 inches.

Specimen # 15

ML 73-3355

Skull - intact

Mandible

C 3, 4, 6, 7 (1, 2, 5 missing)

T 1-12

L 1-5

Sacrum

R + L ilia stage 2 fusion

L ribs 1-12

R ribs 2-12 (# 1 missing)

- fresh or recent f.p. R 8, 9, 10

bifid R 7

R + L clavicles dist. TV prot. 0

R + L scapulae - acromion TV coracoid TV
distal angle III

R + L femur

R + L humerus } all
R + L radius } TV
R + L ulna }

R + L tibia

R + L fibula

L patella

Mandible

R - calcaneus, talus, navicular, 1st 2nd 3rd cuneiforms
cuboid

L - calcaneus talus navicular 1st 2nd 3rd cuneiforms
cuboid

R 1st metatarsal + 2 3 4 5

L " " + 2 3 4 5

L 3, 4, 5 metacarpals

2 prof. phalanges

Age 20-21

Ht. 71 1/4 (70-72 1/2)

40 4 Mark

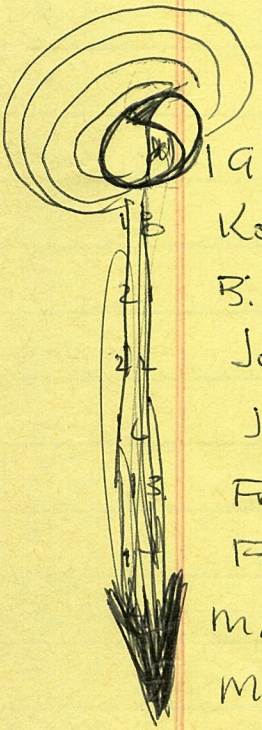
66 Mark Steven Scott W/m 18
66 927 W25
66 disappeared

"Charley"
Haley

Sgt. Rubio, Raymond
Salveston
2517 Ave H
Golds - 77550
409 766 2156

40 4-20-72

6" + 3 1/2



1972 DISAPPEARED

18	Kempner	11-12-72	3366 #19
21	Billy Bitch Bitulch	5- - 72	3413 #26
22	Johnny DeLone	5- - 72	3412 #25
26	John Green	12-8-72	
33	Fred Holmes	3-14-72 *	
34	Frank Aguirre	2-24-72 *	3409 #24
	Mark S. Scott	4-20-72 *	
	Michael Balch	8-21-72	3333 #2
	Dusty McLemore	11- - 72	3350 #12

11, 15, 16, #, (22)
11, 15, 16 (22)

JOSEPH A. JACHIMCZYK, M.D., J.D.

FORENSIC PATHOLOGIST
ATTORNEY AT LAW
CHIEF MEDICAL EXAMINER



228-8311

EXT. 671 (DAY)
EXT. 212 (NIGHT)

#15

OFFICE OF THE MEDICAL EXAMINER
OF HARRIS COUNTY

HARRIS COUNTY COURT HOUSE
HOUSTON, TEXAS 77002

AUTOPSY REPORT

Case 73 - 3355

August 13, 1973

PATHOLOGICAL DIAGNOSIS ON THE BODY


OF

Unknown #15 -

Asphyxia due to strangulation.

OPINION

It is our opinion that the decedent,
Unknown #15, came to his death as a
result of asphyxia due to strangulation -
Homicide.


Joseph A. Jachimczyk, M.D., J.D.
Chief Medical Examiner

(See Companion Cases 73-3332, 73-3333, 73-3334, 73-3335,
73-3336, 73-3337, 73-3338, 73-3339, 73-3347, 73-3348, 73-3349,
73-3350, 73-3353, 73-3354, 73-3356 and 73-3357.)

POSTMORTEM EXAMINATION ON THE BODY OF

UNKNOWN #15

HISTORY: This body was one of seventeen bodies or skeletal remains recovered from Stall #11 at 4500 Silverbell Street, Houston, Texas, between 6:00 p.m. on August 8, 1973, and 8:00 p.m. on August 9, 1973. (See Companion Cases 73-3332, 73-3333, 73-3334, 73-3335, 73-3336, 73-3337, 73-3338, 73-3339, 73-3347, 73-3348, 73-3349, 73-3350, 73-3353, 73-3354, 73-3356 and 73-3357.)

AUTOPSY: The autopsy was performed by Chief Medical Examiner Joseph A. Jachimczyk, M.D., assisted by Assistant Medical Examiners G. Sheldon Green, M.D., and Ethel E. Erickson, M.D., and Dr. Paul G. Stimson, beginning at 3:10 p.m. on August 13, 1973, in the Harris County Morgue.

EXTERNAL APPEARANCE: The specimen consisted of a number of skeletal remains, some soft tissues mostly eaten away with lime, and amorphous plaster-like material, within which the head, long bones, ribs and hair were recognizable. The total weight of the specimen, including the plastic crashbag, was 56 pounds. There was also a strand of nylon cord similar to that seen in the other specimens. The cord was tied tightly around the arms and legs in a bundled up position. This was similar to that seen in the other bodies. The length of the legs was 36 inches from ankle bone up to the tip of the hip bone. The noose was photographed separately and was made up of nylon cord. The hair on the skull was dark brown and measured up to 7-1/2 inches in length. This was an approximate length, because of the scattering of the hair in the total specimen. There were no items of clothing present with these remains. Most of the back was held intact. There was some spinous musculature remaining. Most of the soft tissues, however, were gone. The right 8th, 9th and 10th ribs were fractured, posteriorly. The right 7th rib was a bifid rib.

The remains consisted of the following bones: skull, intact, Caucasian with predominantly male characteristics; mandible, intact; cervical vertebrae 3, 4, 6 and 7 (1, 2 and 5 missing); thoracic vertebrae 1 through 12; lumbar vertebrae 1 through 5; sacrum, right and left ilium, showing stage 2 fusion of the epiphyses of the iliac crests; manubrium; left ribs 1 through 12; right ribs 2 through 12 (1 missing). There were fresh or very recent fractures of right ribs 8, 9 and 10, laterally. Rib 8 was completely broken. Ribs 9 and 10 showed

greenstick type fractures with disruption of the lateral cortex and the medial cortex remaining intact. Right rib 7 was bifid. The right and left clavicles were present. The distal epiphyses showed stage 4 fusion. The proximal epiphyses showed stage 0 fusion. The right and left scapulae were present. The corocoid and achromial epiphyses showed stage 4 fusion. The distal angle epiphyses showed stage 3 fusion. Also present were femur, right and left; tibia, right and left; fibula, right and left; left patella. Right foot, the following bones were present: calcaneus, talus, navicular, 1st, 2nd and 3rd cuneiform, cuboid, the 1st, 2nd, 3rd, 4th and 5th metatarsals. Left foot, the following bones were present: calcaneus, talus, navicular, 1st, 2nd and 3rd cuneiforms, cuboid, 1st, 2nd, 3rd, 4th and 5th metatarsals. The right and left humeri were present. There was stage 4 fusion of both epiphyses. The right and left radii were present, showing stage 4 fusion of the proximal and distal epiphyses. The right and left ulnas were present, showing stage 4 fusion of the proximal and distal epiphyses. The left 3rd, 4th and 5th metacarpals and two proximal phalanges were present.

ESTIMATE OF AGE: The estimate of age was based upon the appearance of the base of the symphysis pubis. The symphysis was traversed by well defined ridge lines, but there was very slight early filling in between the posterior ends of the ridges. There was a well defined dorsal limiting margin. There was no evidence of a ventral bevel. The age was estimated at 20 to 21 years. The remainder of the skeleton was consistent with this age.

ESTIMATE OF HEIGHT: The estimate of height was based on the length of the femur, 50.2 centimeters. The height according to the formula of Trotter and Gleaser, white males, was 71-1/4 inches. A crosscheck for the general formula of Dupersius and Hatten, males, was also 71-1/4 inches. Therefore, the height was estimated to be between 70 and 72-1/2 inches. The bones were moderately, but not unusually heavy. It was estimated that this individual had a medium build or was a medium framed person.

DENTAL EXAMINATION

Utilizing the Universal System, the upper right and left third molars are in the crypts. There is occlusal caries in the upper right second molar, tooth 2. Occlusal caries in the upper right first molar, tooth 3. The upper right lateral and central, the upper left central and lateral are avulsed. These are teeth 7, 8, 9 and 10. There is a diastema present between the upper left cuspid and first bicuspid, tooth 11 and 12. The upper left first molar has occlusal and buccal caries, tooth 14. The upper left second molar has occlusal caries, tooth 15. The lower left third molar, tooth 17, has occlusal caries. The lower left second molar, tooth 18, has mesial occlusal caries. The lower right second molar, tooth 31, has mesial occlusal caries. The lower right third molar, tooth 32, has occlusal caries. Both first lower molars, tooth 19 and tooth 30, have been extracted. The remaining molars have drifted mesially. There is a diastema present between the lower left cuspid and first bicuspid, tooth 22 and tooth 21. Tooth 24 and tooth 25 are in lingual version. Tooth 23 and tooth 26 are in mesial labial rotation. Tooth 22 and tooth 27 in labial version, with slight mesial labial rotation. There is a very high palatal vault with constriction of the maxillary arch. Jaw relationships - there is a Class III on the right side, Class I in the molar area on the left side. Both first molars are in cross-bite. There is an anterior open bite and flaring of the maxillary centrals.



Paul G. Stimson, D.D.S., M.S.

LOCATION: 4500 Silverbell ^{Stall # 11} GRAVE # _____
UNKNOWN # 15 M.E. CASE # 73-3355

IDENTIFIED

NAME: _____

STILL UNKNOWN

I N V E N T O R Y S H E E T

HAIR SAMPLES: _____	AUTOPSY REPORT: ROUGH <u>FINAL</u>
BODY X-RAYS: HCME <u>13</u> OTHER _____	SUPPLEMENTAL: ROUGH FINAL
DENTAL X-RAYS: HCME _____ OTHER _____	INVESTIGATORS REPORT: <u>ROUGH</u> FINAL
HCME PHOTOS: BODY _____ PERSONAL EFFECTS _____	SUPPLEMENTAL: ROUGH FINAL
CLOTHING _____ DENTAL _____	TOXICOLOGY REPORT
PHOTO FROM FAMILY: _____	DENTAL EXAMINATION: ROUGH <u>FINAL FORM</u>
MISSING PERSONS REPORT _____	POINTS OF COMPARISON: ROUGH FINAL FORM
DEATH CERTIFICATE _____	HCME DENTAL CHART _____
BRIEF PHYSICAL DESCRIPTION <input checked="" type="checkbox"/>	OTHER DENTAL CHART _____
SYNOPSIS OF MEDICAL TESTIMONY: _____	EVIDENCE SHEET: _____
CORRESPONDENCE: _____	

COMPARISONS: Jerry Wayne Baldridge - no match 9-10-73
Needs to be checked - Rickie Roy Cape
" " " " - Paul Woodall

David Wayne Waggoner - no match 6-6-86 dental

OTHER: Unknown card
Skeletal chart

Larry Russell dent - no match by dental - 4-2-87
CW+BR

DENTAL: ① In Crypts - # 1, 6 ② Caries # 2, 3, 14, 15, 17, 18, 31, 32 ③ Avulsed - # 7, 8, 9, 10; ④ Diastema present between # 11 + 12, 21 + 22; ⑤ Extracted - # 19, 30; ⑥ Remaining molars drifted mesially ⑦ Lingual version # 24, 25; ⑧ Mesial labial rotation # 23, 26 ⑨ Labial version - # 22, 27; ⑩ Very high palatal vault + c constriction of the maxillary arch; ⑪ Jaw relationships - Class III on rt side - Class I in molar area on left side; ⑫ Both first molars are in crossbite; ⑬ Anterior open bite + flaring of maxillary centrals.

no COUNTY BURIAL Long term cooler
PHOTOS CAN BE VIEWED Skeletal remains
UNIDENTIFIED

PRESS CONFERENCE

3-11-91
DATE

ML# 73-3355 (#15)

DATE OF DEATH: 8-9-73 TIME: found 7:30pm

LOCATION: 4500 Silverbell

RACE: W SEX: M AGE: 20-21

HEIGHT: 70-72 1/2 est. WEIGHT: Med build

EYE COLOR: N/A HAIR COLOR: Dark brown LENGTH: 7 1/2"

FACIAL HAIR & COLOR: N/A

SCARS, MARKS & TATTOOS: N/A

CLOTHING: None

PERSONAL EFFECTS: None

OTHER: Dental: In crypts - # 1, 6; Caries - # 2, 3, 14, 15, 17, 18, 31, 32; Avulsed - # 7, 8, 9, 10; Diastema present between # 11+12 - 21+22; (over)

CAUSE: Asphyxia due to strangulation

POLICE AGENCY: NPD

CASE #:

not NO HIT BY PRINTS
available

Dr. Jachmczyk

Dental (Continued):

Extracted - #19, 30; remaining molars drifted
mesially; Lingual version - #24, 25; Mesial
labial rotation - #23, 26; Labial version - #22, 27,
Very high palatal vault + construction of the
maxillary arch; Jaw relationships - Class II
on rt. side; Class I in molar area on left
side; Both first molars are in cross bite;
Anterior open bite + flaring of maxillary
centrals.

BODY CAN BE VIEWED: YES _____ NO _____

DATE: _____

15

ML 73-3355

SEX: W

SCARS: Skeleton

RACE: M

TATTOOS: _____

EST. AGE: 20-21

OTHER: Bifid R7 rib

HEIGHT: 70" - 72 1/2"

Fresh or very recent fractures R 8, 9, 10 ribs

WEIGHT: Med. Build

X-RAY: _____

EYES: _____

CLOTHING: None

HAIR: dk brown 7 1/2 inches

PERSONAL EFFECTS: _____

DECEDENT'S NAME: _____

DECEDENT'S ADDRESS: _____

NEXT OF KIN: _____

ADDRESS: _____

IDENTIFIED BY: _____ DATE: _____

ADDRESS: _____

HCME OFFICER PRESENT: _____

HARRIS COUNTY MEDICAL EXAMINER

ML# 73-3355

UNIDENTIFIED BODY ANTHROPOMETRY CHART

PP _____ OF _____

PHYSICAL ATTRIBUTE	SUPPORTING INDICATOR
From Autopsy & Investigator Reports	Information from family of Mark Scott
White Male	White Male
Height: 70" to 72½"	Estimated height: 72"
Weight: Medium build	Date of birth: 7-26-54 (17 in 1972)
Clothing: none	
Lower right first bicuspid	Chipped jaw tooth on the right.
Chipped on buccal surface.	
Diastema between maxillary central	
Incisors apparent in 1972	Spaces in upper front teeth.
Photograph exhibit #7.	
Flaring of maxillary central	Front teeth extra big.
incisors.	_____ 0 _____
Body was buried in boat shed.	Original claim of Henley and Brooks
Hair from shoe box matches.	Shoe box furnished by Mr. Walter
Hair from 73-3355 and from Jeffrey	Scott containing hair clipping from
Scott.	his sons Mark and Jeffrey Scott.
Video superimposition 73-3355	
skull over 1972 photograph	Texas Department of Public Safety
of Mark Scott matches.	Karen Taylor, forensic artist.
98.5 probability that DNA recovered	
from bone of 73-3355 is that of	Source: Dr. Elizabeth Johnson's
Mark Scott.	report, dated December 27, 1993.

JOSEPH A. JACHIMCZYK, M.D., J.D.
FORENSIC PATHOLOGIST
ATTORNEY AT LAW
CHIEF MEDICAL EXAMINER



228-8311
EXT. 671 (DAY)
EXT. 212 (NIGHT)

OFFICE OF THE MEDICAL EXAMINER
OF HARRIS COUNTY

HARRIS COUNTY COURT HOUSE
HOUSTON, TEXAS 77002

AUTOPSY REPORT

Case 73 - 3355

August 13, 1973

PATHOLOGICAL DIAGNOSIS ON THE BODY


OF

Unknown #15

Asphyxia due to strangulation.

OPINION

It is our opinion that the decedent,
Unknown #15, came to his death as a
result of asphyxia due to strangulation -
Homicide.


Joseph A. Jachimczyk, M.D., J.D.
Chief Medical Examiner

(See Companion Cases 73-3332, 73-3333, 73-3334, 73-3335,
73-3336, 73-3337, 73-3338, 73-3339, 73-3347, 73-3348, 73-3349,
73-3350, 73-3353, 73-3354, 73-3356 and 73-3357.)

POSTMORTEM EXAMINATION ON THE BODY OF

UNKNOWN #15

HISTORY: This body was one of seventeen bodies or skeletal remains recovered from Stall #11 at 4500 Silverbell Street, Houston, Texas, between 6:00 p.m. on August 8, 1973, and 8:00 p.m. on August 9, 1973. (See Companion Cases 73-3332, 73-3333, 73-3334, 73-3335, 73-3336, 73-3337, 73-3338, 73-3339, 73-3347, 73-3348, 73-3349, 73-3350, 73-3353, 73-3354, 73-3356 and 73-3357.)

AUTOPSY: The autopsy was performed by Chief Medical Examiner Joseph A. Jachimczyk, M.D., assisted by Assistant Medical Examiners G. Sheldon Green, M.D., and Ethel E. Erickson, M.D., and Dr. Paul G. Stimson, beginning at 3:10 p.m. on August 13, 1973, in the Harris County Morgue.

EXTERNAL APPEARANCE: The specimen consisted of a number of skeletal remains, some soft tissues mostly eaten away with lime, and amorphous plaster-like material, within which the head, long bones, ribs and hair were recognizable. The total weight of the specimen, including the plastic crashbag, was 56 pounds. There was also a strand of nylon cord similar to that seen in the other specimens. The cord was tied tightly around the arms and legs in a bundled up position. This was similar to that seen in the other bodies. The length of the legs was 36 inches from ankle bone up to the tip of the hip bone. The noose was photographed separately and was made up of nylon cord. The hair on the skull was dark brown and measured up to 7-1/2 inches in length. This was an approximate length, because of the scattering of the hair in the total specimen. There were no items of clothing present with these remains. Most of the back was held intact. There was some spinous musculature remaining. Most of the soft tissues, however, were gone. The right 8th, 9th and 10th ribs were fractured, posteriorly. The right 7th rib was a bifid rib.

The remains consisted of the following bones: skull, intact, Caucasian with predominantly male characteristics; mandible, intact; cervical vertebrae 3, 4, 6 and 7 (1, 2 and 5 missing); thoracic vertebrae 1 through 12; lumbar vertebrae 1 through 5; sacrum, right and left ilium, showing stage 2 fusion of the epiphyses of the iliac crests; manubrium; left ribs 1 through 12; right ribs 2 through 12 (1 missing). There were fresh or very recent fractures of right ribs 8, 9 and 10, laterally. Rib 8 was completely broken. Ribs 9 and 10 showed

greenstick type fractures with disruption of the lateral cortex and the medial cortex remaining intact. Right rib 7 was bifid. The right and left clavicles were present. The distal epiphyses showed stage 4 fusion. The proximal epiphyses showed stage 0 fusion. The right and left scapulae were present. The corocoid and achromial epiphyses showed stage 4 fusion. The distal angle epiphyses showed stage 3 fusion. Also present were femur, right and left; tibia, right and left; fibula, right and left; left patella. Right foot, the following bones were present: calcaneus, talus, navicular, 1st, 2nd and 3rd cuneiform, cuboid, the 1st, 2nd, 3rd, 4th and 5th metatarsals. Left foot, the following bones were present: calcaneus, talus, navicular, 1st, 2nd and 3rd cuneiforms, cuboid, 1st, 2nd, 3rd, 4th and 5th metatarsals. The right and left humeri were present. There was stage 4 fusion of both epiphyses. The right and left radii were present, showing stage 4 fusion of the proximal and distal epiphyses. The right and left ulnas were present, showing stage 4 fusion of the proximal and distal epiphyses. The left 3rd, 4th and 5th metacarpals and two proximal phalanges were present.

ESTIMATE OF AGE: The estimate of age was based upon the appearance of the base of the symphysis pubis. The symphysis was traversed by well defined ridge lines, but there was very slight early filling in between the posterior ends of the ridges. There was a well defined dorsal limiting margin. There was no evidence of a ventral bevel. The age was estimated at 20 to 21 years. The remainder of the skeleton was consistent with this age.

ESTIMATE OF HEIGHT: The estimate of height was based on the length of the femur, 50.2 centimeters. The height according to the formula of Trotter and Gleaser, white males, was 71-1/4 inches. A crosscheck for the general formula of Dupersius and Hatten, males, was also 71-1/4 inches. Therefore, the height was estimated to be between 70 and 72-1/2 inches. The bones were moderately, but not unusually heavy. It was estimated that this individual had a medium build or was a medium framed person.

DENTAL EXAMINATION

Utilizing the Universal System, the upper right and left third molars are in the crypts. There is occlusal caries in the upper right second molar, tooth 2. Occlusal caries in the upper right first molar, tooth 3. The upper right lateral and central, the upper left central and lateral are avulsed. These are teeth 7, 8, 9 and 10. There is a diastema present between the upper left cuspid and first bicuspid, tooth 11 and 12. The upper left first molar has occlusal and buccal caries, tooth 14. The upper left second molar has occlusal caries, tooth 15. The lower left third molar, tooth 17, has occlusal caries. The lower left second molar, tooth 18, has mesial occlusal caries. The lower right second molar, tooth 31, has mesial occlusal caries. The lower right third molar, tooth 32, has occlusal caries. Both first lower molars, tooth 19 and tooth 30, have been extracted. The remaining molars have drifted mesially. There is a diastema present between the lower left cuspid and first bicuspid, tooth 22 and tooth 21. Tooth 24 and tooth 25 are in lingual version. Tooth 23 and tooth 26 are in mesial labial rotation. Tooth 22 and tooth 27 in labial version, with slight mesial labial rotation. There is a very high palatal vault with constriction of the maxillary arch. Jaw relationships - there is a Class III on the right side, Class I in the molar area on the left side. Both first molars are in cross-bite. There is an anterior open bite and flaring of the maxillary centrals.



Paul G. Stimson, D.D.S., M.S.

JOSEPH A. JACHIMCZYK, M.D., J.D.

FORENSIC PATHOLOGIST

ATTORNEY AT LAW

CHIEF MEDICAL EXAMINER




EXHIBIT # 5

(713) 796-9292

(713) 796-6815

FAX: (713) 796-6838



OFFICE OF THE MEDICAL EXAMINER OF HARRIS COUNTY

JOSEPH A. JACHIMCZYK FORENSIC CENTER

**1885 OLD SPANISH TRAIL
HOUSTON, TEXAS 77054-2098**

December 27, 1993

Case : ML73-3355

Subject: Final Report of DNA Analysis

The following items pertaining to case #ML73-3355 were received in our DNA laboratory on October 14, 1992 for the purpose of mitochondrial DNA comparison:

1. Blood from Mary Scott, maternal reference
2. Bone sample (femur), from skeletal remains presumptively identified as those of Mark Scott.

A DNA extraction process was performed on each of the above samples. The extracted DNA was PCR amplified and sequenced in the hypervariable (HVR) regions 1 and 2 of the mitochondrial D-loop.


Sequence information consisting of approximately 600 bases was obtained for both the reference sample and the unknown bone sample.

The DNA sequences of the reference sample and the unknown bone sample are identical to each other in the 595 base overlapping region (see Appendix I). This implies a maternal relationship between the two samples.

The DNA sequence obtained from the maternal reference and unknown bone sample was compared to a database consisting of sequence information from 203 unrelated Caucasians; approximately 536 bases of sequence information in this database were available for comparison to the case samples. The DNA sequence obtained from Mary Scott and the unknown bone sample occurs in 3 of 203 individuals in this database. Therefore, approximately 1.5% of Caucasians would carry this sequence.

Conclusion:

On the basis of mitochondrial DNA analysis, the unknown bone sample from ML73-3355 cannot be excluded as originating from the biological offspring of Mary Scott.


Elizabeth A. Johnson, Ph.D.

APPENDIX I

ALIGNMENT OF OVERLAPPING SEQUENCE IN HYPERVARIABLE REGION 1

MSHVR1 - Mary Scott Reference
 Total number of bases: 385

73BHVR1 - CL73-3355 bone
 Total number of bases: 385

```

16014
MSHVR1 - CTATPCTCTGTTCTTTCATGGAGAAGCAGATTTGGGTACCACCCAAGTAT -50
          |||
73BHVR1 - CTATPCTCTGTTCTTTCATGGAGAAGCAGATTTGGGTACCACCCAAGTAT -50
          |||
MSHVR1 - TGACTCACCCATCAACAACCGCTATGTATTTTCGTACATTACTGCCAGCCA -100
          |||
73BHVR1 - TGACTCACCCATCAACAACCGCTATGTATTTTCGTACATTACTGCCAGCCA -100
          |||
MSHVR1 - CCATGAATATTGTACGGTACCATAAATACTTGACCACCTGTAGTACATAA -150
          |||
73BHVR1 - CCATGAATATTGTACGGTACCATAAATACTTGACCACCTGTAGTACATAA -150
          |||
MSHVR1 - AAACCCAATCCACATCAAACCCCTCCCCATGCTTACAAGCAAGTACAG -200
          |||
73BHVR1 - AAACCCAATCCACATCAAACCCCTCCCCATGCTTACAAGCAAGTACAG -200
          |||
MSHVR1 - CAATCAACCCTCAACTATCACACATCAACTGCAACTCCAAAGCCACCCT -250
          |||
73BHVR1 - CAATCAACCCTCAACTATCACACATCAACTGCAACTCCAAAGCCACCCT -250
          |||
MSHVR1 - CACCCACTAGGATACCAACAAACCTACCCACCCTTAACAGTACATAGTAC -300
          |||
73BHVR1 - CACCCACTAGGATACCAACAAACCTACCCACCCTTAACAGTACATAGTAC -300
          |||
MSHVR1 - ATAAAGCCATTTACCGTACATAGCACATTACAGTCAAATCCCTTCTCGTC -350
          |||
73BHVR1 - ATAAAGCCATTTACCGTACATAGCACATTACAGTCAAATCCCTTCTCGTC -350
          |||
MSHVR1 - CCCATGGATGACCCCCCTCAGATAGGGGTCCCTTG -385
          |||
73BHVR1 - CCCATGGATGACCCCCCTCAGATAGGGGTCCCTTG -385
          |||
    
```

ALIGNMENT OF OVERLAPPING SEQUENCE IN HYPERVARIABLE REGION 2

MSHVR2 - Mary Scott Reference
Total number of bases: 210

73BHVR2 - CL73-3355 bone
Total number of bases: 210

```

      57
MSHVR2  - TTTTCGTCTGGGGGGTATGCACGCGATAGCATTGCGAGACGCTGGAGCCG -50
          |||
73BHVR2  - TTTTCGTCTGGGGGGTATGCACGCGATAGCATTGCGAGACGCTGGAGCCG -50
          |||
MSHVR2  - GAGCACCTATGTCGCAGTATCTGTCTTTGATTCCTGCCTCATCCTATTA -100
          |||
73BHVR2  - GAGCACCTATGTCGCAGTATCTGTCTTTGATTCCTGCCTCATCCTATTA -100
          |||
MSHVR2  - TTTATCGCACCTACGTTCAATATTACAGGCGAACATACTTACTAAAGTGT -150
          |||
73BHVR2  - TTTATCGCACCTACGTTCAATATTACAGGCGAACATACTTACTAAAGTGT -150
          |||
MSHVR2  - GTTAATTAATTAATGCTTGTAGGACATAATAATAACAATTGAATGTCTGC -200
          |||
73BHVR2  - GTTAATTAATTANTGCTTGTAGGACATAATAANAACAATTGAATGTCTGC -200
          |||
MSHVR2  - ACAGCCACTT -210
          |||
73BHVR2  - ACAGCCACTT -210
          |||
                266
```

An "N" denotes an unreadable/unconfirmed base

JOSEPH A. JACHIMCZYK, M.D., J.D.

FORENSIC PATHOLOGIST

ATTORNEY AT LAW

CHIEF MEDICAL EXAMINER



(713) 796-9292

(713) 796-6815



OFFICE OF THE MEDICAL EXAMINER OF HARRIS COUNTY
JOSEPH A. JACHIMCZYK FORENSIC CENTER

1885 OLD SPANISH TRAIL
HOUSTON, TEXAS 77054

March 20, 1991

Mr. Jim Bolding
Houston Police Department
#1 Artesian Place
Houston, Texas 77002

Dear Mr. Bolding:

Submitted herewith are scapulae from the following
medical legal cases:

73-3349

73-3355

73-3356

89-5901

It is requested that, if possible, DNA extracts be obtained from these specimens. Cases 73-3349, 73-3355 and 73-3356 are unidentified remains from homicides within the Houston Police Department jurisdiction. Each was recovered from a boatshed on Silverbell Street in southwest Houston in 1973, part of the so called mass murders by Corll, Henley and Brooks. Each is a caucasian male.

Medical legal 89-5901 is a homicide, Houston Police Department jurisdiction, unknown remains of a caucasian female, possibly hispanic.

Mr. Bolding

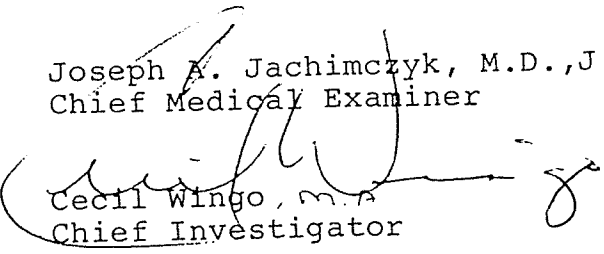
Page 2

We have "possible and even probable" matches for each of these unknowns. There are living parents and/or siblings for each from whom we can obtain blood specimens for possible DNA crossmatching. If there is success in one or all of these it would provide an identification totally unavailable in any other manner. To our knowledge this would also be a first such identification.

Your assistance is greatly appreciated.

Sincerely,

Joseph A. Jachimczyk, M.D., J.D.
Chief Medical Examiner


Cecil Wingo, M.D.
Chief Investigator

CW/pb

STR
Houston Police Crime Laboratory
REF: L91-3332

Date: December 2, 91.

The following samples were received from Medical examiner's office at Houston for DNA Profiling:

REF #	TEST MATERIAL	DATE RECEIVED	PROBE(LOCUS)
ML89-5901	Bone Scapula (DECEDANT)	3-21-91)	(YNH24(D2S44)
	Blood(R.R.ESPINOZA, *PF)	4-16-91)	(TBQ7(D10S28)
	Blood(Munoz, A, *PM)	4-16-91)	(MS1(D1S7) (V1(D17S79)
ML73-3356	Bone Scapula (DECEDANT)	3-21-91	YNH24(D2S44)
	Blood(BRYCE FERDIQ, *PF)	5-13-91	YNH24(D2S44)
	Blood(ERMA L. SICKMAN, *PM)	5-13-91	YNH24(D2S44)
ML73-3355	Bone Scapula (DECEDANT)	3-21-91	YNH24(D2S44)
	Blood(WALTER SCOT, *PF)	5-13-91	YNH24(D2S44)
	Blood(MARY SCOT, *PM)	5-13-91	YNH24(D2S44)
ML73-3349	Bone Scapula (DECEDANT)	3-21-91	YNH24(D2S44)
	Blood(IKE PRATER, *PF)	5-13-91	YNH24(D2S44)
	Blood(RHONDA PRATER, *PM)	5-13-91	YNH24(D2S44)

DNA was isolated from all of the above listed sample and processed for DNA profiling as per FBI protocol.

Results and conclusions:

Results are inconclusive because the DNA isolated from bones in all cases was degraded and did not yield any results. DNA from blood in all cases yielded two banded patterns with all the probes tested

*PF= Possible Father. PM=Possible Mother

B.R. Sharma
Baldev R. Sharma,
Criminalist II

12-2-91

*RCV
12-6-91
aw*

159 → X-ray file

A MONTH CALENDAR						
JULY						
1	2	3	4	5	6	7
8	9	10	11	12	13	14
15	16	17	18	19	20	21
22	23	24	25	26	27	28
29	30	31				
AUGUST						
1	2	3	4	5	6	7
8	9	10	11	12	13	14
15	16	17	18	19	20	21
22	23	24	25	26	27	28
29	30	31				
SEPTEMBER						
1	2	3	4	5	6	7
8	9	10	11	12	13	14
15	16	17	18	19	20	21
22	23	24	25	26	27	28
29	30	31				
OCTOBER						
1	2	3	4	5	6	7
8	9	10	11	12	13	14
15	16	17	18	19	20	21
22	23	24	25	26	27	28
29	30	31				
NOVEMBER						
1	2	3	4	5	6	7
8	9	10	11	12	13	14
15	16	17	18	19	20	21
22	23	24	25	26	27	28
29	30					
DECEMBER						
1	2	3	4	5	6	7
8	9	10	11	12	13	14
15	16	17	18	19	20	21
22	23	24	25	26	27	28
29	30	31				

9-18-73

re: Mark Scott

Re
Dr. A. D. O. McCary

Hospital Road
Freeport

9-19-73
Mark Scott
referred
to
Dr. O. D. McCary
has been destroyed
he has further
re books will
be further
collected

Mark Steven Scott

Jeffrey Lynn Scott

→ worked for R.R.; left
in 1964

- just below him in a
duplex at one time -

- Nurse - Mrs. Pennington

Walter Tom Scott
CN 2-8558

circumcised?
yes

disappeared
Apr 20, 1972.

Dr. Waller

Mark Scott

severely mutilated

Mary
mother

Post # 12

- ① spaces in ~~upper~~ front teeth
- ② braided leather ^{bound} ~~bound~~ ⁽⁴⁾ by Brooks
- ③ statement re ~~de-~~ balling
- ④ side tany pellet at femur epiphyseal end ^{bone}
- ⑤ Height Xray approx 1 yr before shows at femur ^{two pellets -}

Re: Richard Rieby

missy 10-

5-5
105

✓
thick r
loose

Mr + Mrs W M
869-560

GSW rt check

statement of

Re: Richard Rieby

missy 10-

5-5
105

✓
thick r
loose

Mr + Mrs W M
869-560

GSW rt check

statement of

4-20-72

dob 7-26-

Walter Donn Scott - UN-2-8558 father
Mark Steven Scott wm 19 6' 160-170 lbs

no broken bones - ^{no} dental records

fingerpriced by

FOPD - for carrying 4" knife approx 9.70 ~~4#~~

(Mrs Hosp -
shot in leg pellet gun
2 + 3 yrs. ago)

Dr. Waller - Durham
20th St. Clinic

73-3350

#12

8:10 am

8-23-73

10:30 A.M.

Dr. Jachmazyk

Mr. Scott

UN 2-8558

8:25 am

2/18/74

Walter Scott

862-2506

after 5pm

Wants picture of
teeth in body

#12

TELEPHONE MESSAGE

Date 11-12-73

For Mr. J

From Walter Scott

Their No. UN28558 Time Rec'd 10 AM

Remarks: Please call

- Urgent
- chipped jaw tooth on right
 - chain around neck -
 - visit, watch - Tim WB

EFFICIENCY LINE NO. 2765

10-2-73						
MAY						
JUNE						
JULY						

re: Mark Scott

April 20 - July 17, 1972

NEXT MONTH						
LAST MONTH						
MAY						
JUNE						
JULY						

rented Feb 1, 1972
located July 17, 1972

Shuler St Apt.

Mark Steven Scott wml9 dis. 4-20-72 ^{17 1/2} d.o.b. 7-26-54 6' 160-170 lb.
Blond ^{approx} ~~approx~~ shoulder length hair.

Walter Tom Scott - father un-2-8558
no broken bones - no dental work


*his J.N.
a release.*

Fingerprinted by H.P.D. for carrying 4" knife approx. 1970

Dr. Waller - Durham Clinic family physician.

was shot by David Brooks in the leg with a pellet gun approx. 2 or 3 years ago. Heights Hospital

no knowledge of clothing. ^{usually wore} (short sleeve knit shirts + blue jeans, desert boots 10 1/2 D size.

From the desk of... PAT GROTTIS 10-3-73
Dr. Jackson
8:20 AM 10-3-73
Mr. Scott
UN-2-8558
from Nancy Bellis


Lois

Cecil Call

Lois at GIBSON

445-9336,
445

Right away.

12009 Wilkie Lane
~~76007~~
77076

JB
Mail pictures to Lois
Pictures mailed 8-29-88

DOB-7-26-54

NAME: Mark Steven Scott

DATE LAST KNOWN ALIVE: 4-20-72

DATE REPORT FILED: 8-23-73

REPORT FILED	POLICE AGENCY	FRIEND
<i>with us by:</i>	<u>RELATIVE</u>	OTHER _____

DENTAL CHART: YES NO

BODY X-RAYS: YES NO

PHOTOGRAPH: YES NO

OTHER: _____

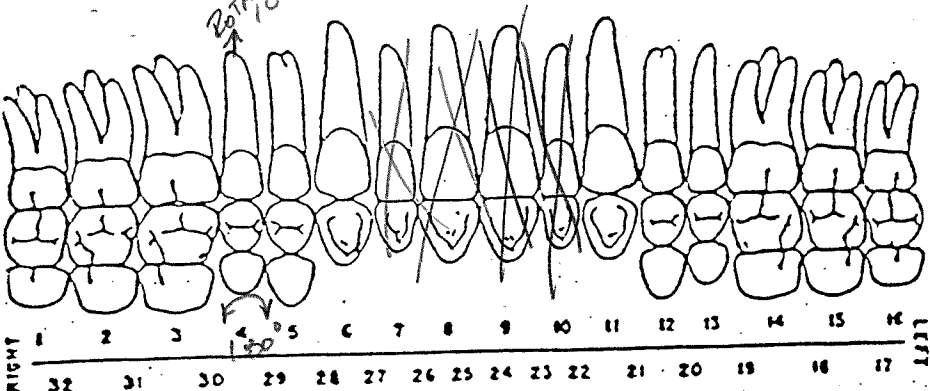
POSSIBILITIES: _____

COMPARISONS MADE: _____

OTHER: _____

X ON ALL EXISTING RESTORATIONS AND MISSING TEETH ON THIS CHART

Estimated Age _____
 Sex _____
 Race _____



73-3355

Circle descriptive term

Prosthetic Appliances
 Present — Maxilla

Full Denture

Partial Denture

Fixed Bridge

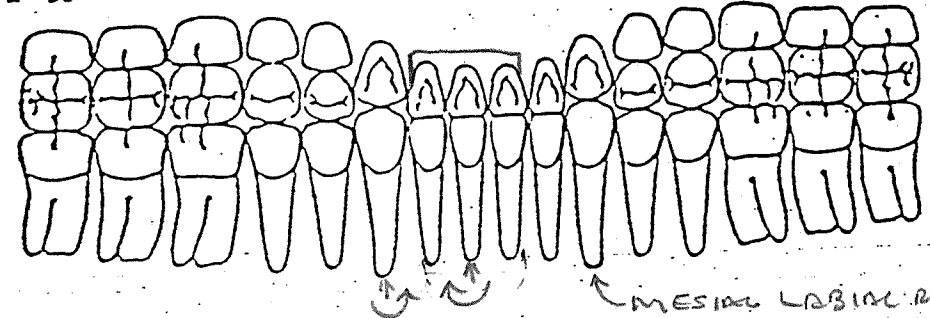
PALATAL VAULT
 SHALLOW
 NORMAL
 HIGH

Prosthetic Appliances
 Present — Mandible

Full Denture

Partial Denture

Fixed Bridge



Describe completely all Prosthetic Appliances or

Fixed Bridges: #9 & #10 AVULSED. #4 HAS ROTATED 180°, BUCCAL AND

LINGUAL CUSPS ARE REVERSED. #22 IS IN MESIAL LABIAL

ROTATION. #25 IS IN LINGUAL VERSION, BLOCKED OUT BY

TOOTH 24 & 26. #27 IS IN MESIAL LABIAL ROTATION

Stains on
 teeth
 Slight
 Moderate
 Severe

MARK ALL CARIES

TEETH ON THIS CHART

Outline all caries

Circle descriptive term

Jaw Relationship

Normal

Undershot

Overbite

Periodontal condition

Excellent

Average

Poor

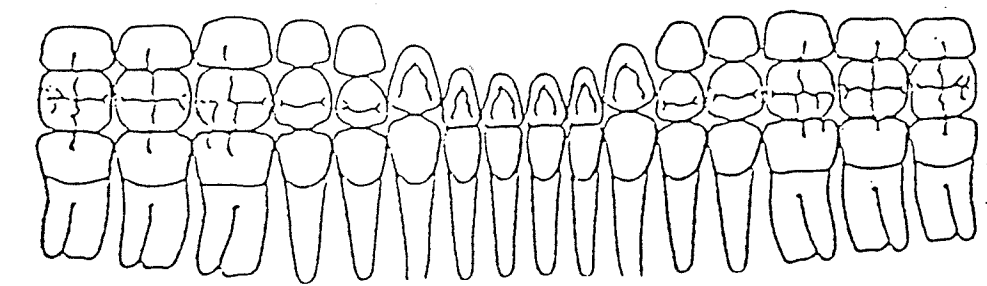
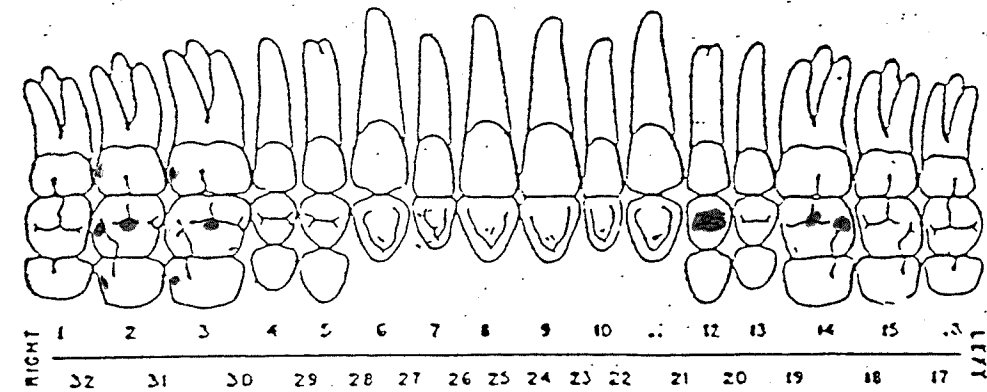
Gross Neglect

Calculus

Slight

Moderate

Severe



1177+ STUDEWOOD

Killed

HILLIGIST BOAT 5

WINKLE BS

COBBLE BS

JONES BS

LAWRENCE RAYBURN

HAINY HI AT B.S.

DELONE HI

BAUCH B HI ~~BS~~

BAUCH M R AT-BS

SCOTT BS

AGUIRRE HI

GARCIA R

12

LAMAR

AM
STATEMENT

Brooks

EXHIBIT #2

	2	YORKTOWN TOWN HOUSE	NO NAMES	
	1	SAN FIPE	RUBEN HAINUP	ID
	2	MANGAM	WALDROP BOYS	ID
				ID
	1	COLUMBIA		RANDAL LEE HARVEY?
	1	COLUMBIA	GLASS	ID XXXX
# 15	1	SCHILLER	SCOTT	XXXX BOAT
	1	"	BAUCH	
	1	"	MALONE	
	1	"	TALL - SKINNY	KOMEN ?
	1	WESCOTT TOWERS	SHOT JAW	HEMBRE
	1	" "		YATES ?
	1	PACIFIA APTS		MEXICAN ?
	1	PASADENA		#20
16	1	↑		LAURENCE
	1		PICTURE LAKE	

PM
STATEMENT